

# **Brachial Plexus Injuries: Surgical Repair After Root Avulsions**

Authors: Mariano Socolovsky (1), Eduardo Fernández (2)

Setting:

(1) Division of Neurosurgery. Instituto de Neurociencias Aplicadas (Applied Neuroscience Institute). Hospital de Clínicas "José de San Martín". School of Medicine. University of Buenos Aires. Argentina

(2) Department of Neurosurgery, Catholic University of Rome, Italy.

Telephone number: 005411-4706-0954

Fax: 005411-4706-0954

E-mail: socolovsky@intramed.net.ar

## **Introduction**

Pioneers in brachial plexus injury (BPI) reconstructive surgery such as Algimatas Narakas, Hanno Millesi and Jean-Yves Alnot generated significant enthusiasm in the 70s and 80s owing to the innovative techniques that they developed along with several other authors (1,2,28,29,30,41). In subsequent years, interest for that surgery declined because the evolution of results was stagnant.

In the last and a half decade, however, several original reports on new nerve transfer techniques to neurotize BPI with root avulsion were published (10,11,18,26,35,37,42,44).

The goal of the present review is to discuss published reports on nerve transfer techniques for repairing BPI and to synthesize the relatively extensive information currently available.

## **Materials and Methods**

Medline was searched for specialized literature published between January 1993 and June 2006. This search comprised all keywords connected with traumatic BPI, including end-to-end anastomosis, reconstruction, neurolysis, neurotization, nerve transfer, and outcome in large series.

There were selected 50 on 89 papers related to specific techniques and large series. On this basis, we discuss brachial plexus reconstruction using transfer of different nerves.

## **Discussion**

Neurotization means to connect the proximal stump of an intact nerve (the donor), after being cut, to the distal stump of an injured nerve (the recipient) of which the proximal stump is not available. Loss of function of the donor nerve is unavoidable.

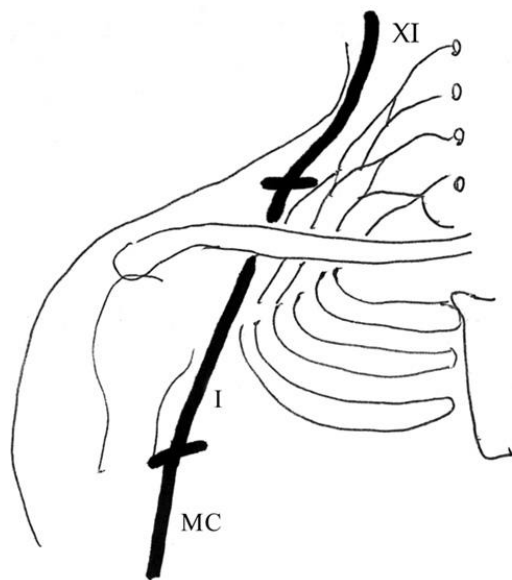
Therefore, the decision to perform a neurotization should depend on a balance between the function of both the donor and the recipient nerve, considering also the success potential of the technique, which never can be secured.

Neurotization can be the procedure of choice when direct nerve reconstruction is impossible like in BPI in which root avulsion from the spinal cord occurs. In brachial plexus surgery, neurotizations can use as donors either extraplexal or/and intraplexal nerves.

Extraplexal neurotizations can be performed using as donors the spinal accessory, intercostal, phrenic and hypoglossal nerves. Also the utilization of the C7 contralateral root can be considered "extraplexal" with respect to the injured brachial plexus of the opposite site.

### *Spinal Accessory Nerve Transfer*

At the present time, the spinal accessory nerve transfer is used to neurotize the musculocutaneous and the suprascapular nerve for restoring elbow flexion and upper extremity abduction-shoulder external rotation, respectively (Figure 1).



Allieu (1) popularized spinal accessory nerve transfer for musculocutaneous nerve neurotization using nerve grafts (Fig. 1). Using this technique in 44 cases, Samii (40) demonstrated how important are early surgery and short nerve graft to obtain good results. Surgery within the first six months and nerve grafts shorter than 12 cm in length were associated to 86% of good results, whereas for later surgery and longer nerve grafts the results were favorable in 65% of the cases.

Malessy (24) neurotized directly the suprascapular nerve with spinal accessory nerve transfer in a series of 53 patients. Only in 9 of them (17%) the strength of the supraspinous muscle was 3 or 4 of the British Medical Research Council (BMRC) scale and a 45° shoulder abduction was obtained only in 8 patients. These findings are in contrast to those reported by Terzis (45) that repaired the suprascapular nerve in 118 patients obtaining good or excellent results in 93 of them, 80 of which underwent spinal accessory nerve transfer.

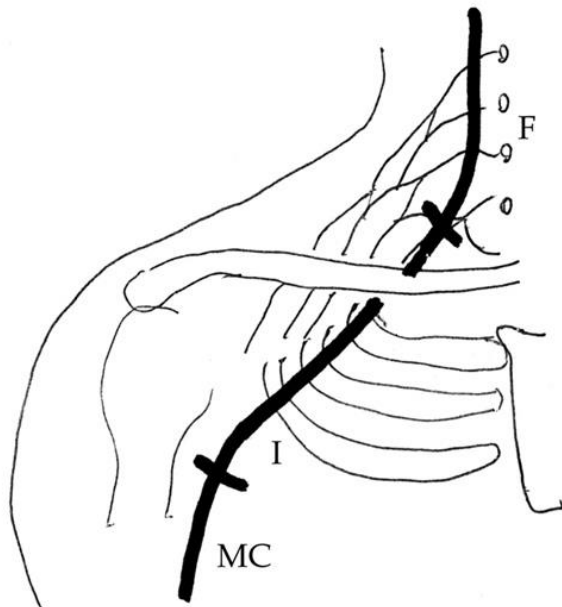
Recently, Guan Shi-bing (16) described a nerve transfer technique using a distal branch of the spinal accessory nerve to repair the suprascapular nerve through a

dorsal approach. This technique has the advantage of reducing the distance to the target muscle as well as the entity of trapezius muscle denervation. Another important aspect is that this technique permits to overcome the scapular notch that can be a site of a second injury of the suprascapular nerve. This second injury can be largely unnoticed when using the classical anterior supraclavicular approach. Using this technique of SAN transfer in 11 patients, Guan Shi-bing refers 11 good results.

Bertelli (4) described a simple and reliable technique for harvesting the spinal accessory nerve in the neck. As no electrical stimulation is required for nerve identification in this procedure, both nerve identification and dissection are simpler.

#### *Phrenic Nerve Transfer*

The phrenic nerve is generally isolated at the cervical level to neurotize BPI with root avulsions (14) (Figure 2).



The largest reported series of phrenic nerve transfer to neurotize several nerves (13) is related to 180 patients operated on between 1970 and 1990. Sixty-five cases had a follow-up over two years and in 49 of these, the phrenic nerve was used to neurotize the musculocutaneous nerve. A direct suture was performed in 40 and a sural nerve graft in 9. Thirty-two out of the 40 patients with direct repair scored BMRC 3-5 in biceps contraction (Table 1), and 8 were unsuccessful. The results obtained using nerve graft were similar. The time of nerve repair was prognostically important. When the average was 290 days, biceps strength scored 4-5, whereas 656 days was the average in cases that scored 1-2.

Pulmonary function was affected in only one patient. This case was a 5-year-old child who underwent simultaneous sacrifice of the PN and the 5th, 6th and 7th intercostal nerves. This resulted in respiratory failure that required intensive care unit management for several weeks. However, one year after surgery only in 32

out of 65 patients, diaphragmatic contraction was good, 19 showing a subclinical reduction of global pulmonary capacity that improved after two years.

In a less large series, Luedeman et al (21) analyzed 23 cases of phrenic nerve transfer to neurotize the musculocutaneous nerve. Pre- and post-operative pulmonary function was evaluated in 12 cases.

A nerve graft was used in 18 cases. Biceps contraction reached a score of 4-5 in 58% of patients.

No patient had postoperative pulmonary impairment, although an average of around 10% vital capacity reduction occurred. Sacrifice of the right phrenic nerve produced a higher percentage of respiratory impairment than that of the left phrenic nerve. This finding might be due to the larger surface and greater functional importance of the right diaphragm in pulmonary ventilation.

The mild vital capacity reduction after phrenic nerve transfer was confirmed by Chalidapong (8).

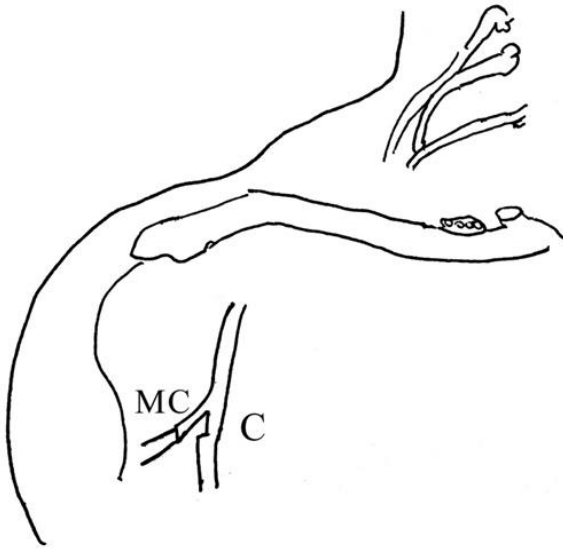
The first postoperative year, the pulmonary capacity was reduced after phrenic nerve transfer. He noted also that such function was normal three months after intercostal nerve transfers.

Finally, the phrenic nerve harvesting technique described by Xu et al (49) should be mentioned. This video-assisted thoracic surgery technique permits to obtain a longer phrenic nerve ( $12.3 \text{ cm} \pm 4.5 \text{ cm}$ ) and then to avoid the use of nerve to neurotize the musculocutaneous. The results consisted in a 3 or higher biceps strength in 8 of 11 cases. However, a comparative study between phrenic nerve transfer to the musculocutaneous by direct suture or with interposition of a nerve graft remains to be done.

#### *Ulnar Nerve Transfer*

After Oberlin (31) reported 4 cases of successful biceps reinnervation using some ulnar nerve fascicles, an increased interest originated in applying this technique to treat C5, C6 and C7 root injuries.

The transfer of some ulnar nerve fascicles permits complete functional preservation of the ulnar nerve (Fig. 3).



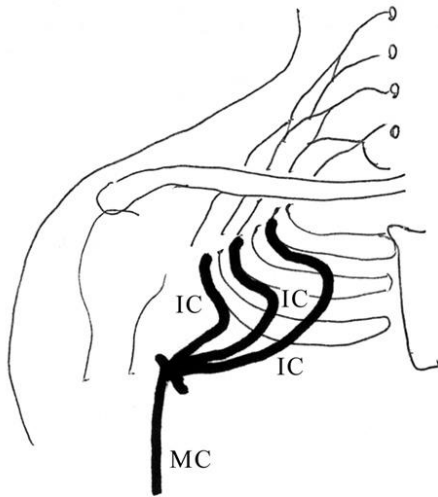
In a subsequent series, Oberlin (32) reported that only 2 patients on 29 had not biceps function recovery. The report also stresses that C5-C6 injuries achieved greater biceps strength than C5-C6-C7 injuries.

The largest series (19) studied 32 patients who underwent ulnar nerve transfer to the musculocutaneous and spinal accessory nerve transfer to the supraescapular nerve. The results were good in 93% of cases. Sectioning of one or two fascicles of the ulnar nerve caused only mild and temporary disorders.

More recently, Liverneaux (20) reported a series of 10 patients in which the two collateral branches of the musculocutaneous nerve, that innervating the biceps and the other innervating the anterior brachialis muscles, were directly neurotized by transferring fascicles of the ulnar nerve and of the median nerve, respectively. Tung (47) reported a series of 8 patients treated in a manner similar to that of Oberlin: fascicles of the ulnar nerve were used to neurotize the branch for the biceps whereas the branch for the anterior brachialis muscle was neurotized using several donor nerves like fascicles of the median or the medial pectoral or intercostal nerves. The purpose was to simultaneously reinnervate two synergistic muscles of elbow flexion. The outcome was positive in 100% of patients of both series; there was not morbidity due to the partial section of the ulnar nerve and after two years, a minimum 4 strength was achieved. These promising results should be validated in larger series in the future.

#### *Intercostal Nerve Transfers*

In 1968, Tsuyama and Hara (46) suggested the transfer of two or more intercostal nerves, dissected for a long path below their overlying rib, to neurotize BPI with root avulsions (Fig. 4).



Initially, this method was largely used in the East, where many series were reported throughout the 70s and 80s. All of them showed favorable results, roughly exceeding 50% of biceps reinnervation, with BMRC 3 or higher strength. The anastomosis method, as well as the ideal number of intercostal nerves to be used, is still controversial. The axons of each intercostal nerve are reduced by around 10% every 10 cm of length as it innervates the accessory inspiratory muscles (36). Therefore, if the dissection proceeds as distally as possible, almost up to the sternum, a transfer without graftings will be possible but using intercostal nerves with fewer axons. Conversely, if the intercostal nerve is sectioned proximally, just where the nerve has more axons, a nerve graft will be necessary to perform the transfer procedure. The other issue that has yet not be determined is the number of intercostal nerves required to maximize outcomes. Kawai et al (17) demonstrated that a superior outcome is achieved when two nerves instead of one are used; however, they failed to establish the benefit derived from using more than two nerves.

More recently, Okinaga and Nagano (34) reported on a small series of 5 cases treated with intercostal nerve transfer performing dissection of the nerve with its corresponding feeding intercostal vascular pedicle. The results were essentially similar to those reported after the use of non-vascular intercostal nerves. Therefore, the authors suggest avoiding this technique, as it requires a more complex dissection and a longer operative time.

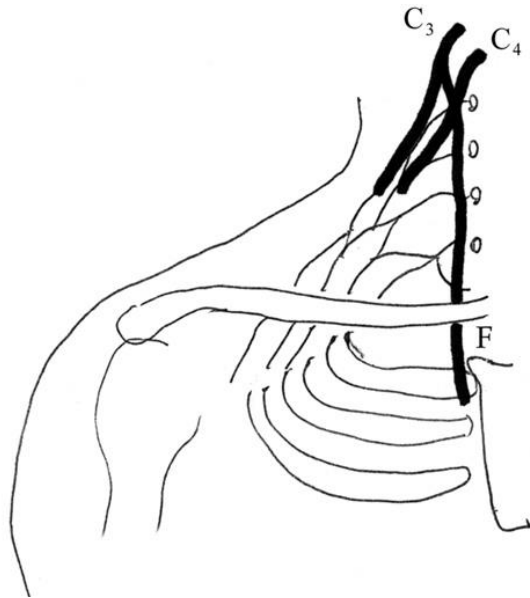
The intercostal nerve transfers were used mostly to neurotize the musculocutaneous nerve or directly the branch of this nerve for the biceps muscle.

Oberlin (33), used an intercostal nerve transfer to neurotize triceps branches, whereas the spinal accessory nerve was used to reinnervate the biceps muscle. According to this author, antagonistic arm muscles are thus turned functional with different axonal sources, which produce superior results.

Interestingly, Malessy (25), using functional brain MR imaging in patients who had undergone successful intercostal nerve transfer for biceps muscle reinnervation, noted that biceps voluntary contraction induced activity in the primary motor cortex.

### *Cervical Root Transfers*

In 1991, Yamada (50) described this transfers for BPI with root avulsions. The anterior primary rami of C3 and C4 cervical roots, just distal to phrenic nerve, are used (Fig 5).



Indeed, this technique was a variant of the procedure originally described by Brunelli, 15 years before (7). Yamada reports a series of 12 patients who underwent C3-C4 root and other nerve transfer procedures, to reinnervate different muscles. Nine patients scored BMRC 3 or higher in some of the explored muscles. It is stressed that early surgery, within six weeks after injury, yields better results than delayed surgery. Furthermore, this method could be particularly indicated for obstetrical brachial plexus palsies, since early age may be crucial to achieve a good outcome. In a commentary on this article, Kline (50) expresses some concerns about the Yamada's results that were rather too favorable, even for muscles in which contractions are usually not clinically evident even when a successful reinnervation occurs, such as for example, the intrinsic muscles of the hand.

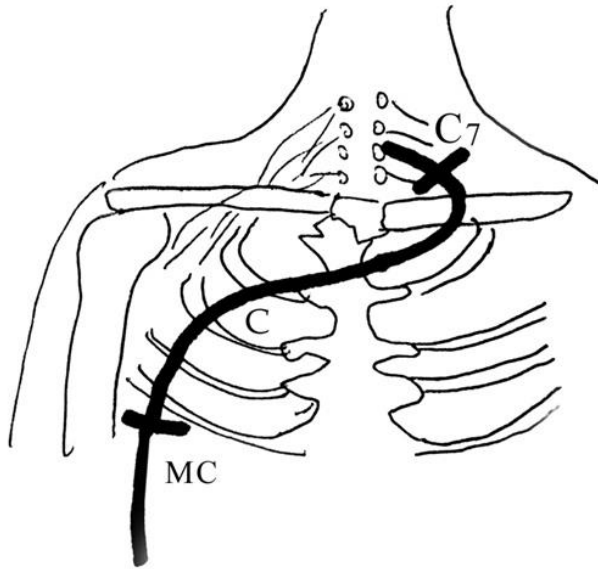
Additionally, Kline is against performing brachial plexus reconstruction surgery within six weeks after injury in partial lesions, since some cases shows a delayed spontaneous function recovery.

### *Contralateral C7 Root Transfer*

This transfer was described by Gu in 1992 (15) to neurotize several nerves. So far, this is the only method that is effective for reinnervation of the muscles innervated by the median nerve.

For using this transfer, it is necessary to dissect: a) the healthy contralateral C7 root with an anterior cervical approach, b) the injured nerve to be neurotized, for example the median nerve, at a proximal brachial level, c) the ulnar nerve with its vascular pedicle from the proximal brachial level up to the wrist. This nerve is

then used as a graft put under a subcutaneous tunnel between the contralateral C7 root and the nerve that must be neurotized (Fig. 6).



The long-term results of this procedure were reported on 20 of 82 patients with a follow-up of more than two years (12). A favorable outcome was obtained in five of six musculocutaneous nerves, six of eight median nerves (neurotized to obtain wrist and finger flexion), three of four radial nerves (neurotized to obtain wrist and finger extension), and one of two latissimus dorsi (neurotized to obtain dynamic arm abduction against the trunk). Around 60% of the cases exhibited a satisfactory motor outcome, scoring BMRC 3 or higher, whereas 78% had a noticeable sensory improvement.

The sacrifice of the contralateral C7 root causes in the healthy upper extremity a variable area of antebrachial sensory loss and a wrist extension motor loss, which is rarely significant and never permanent.

A variation to this technique was described in 2001 by Songcharoen (43). It is advocated to use only half of the 4-6 fascicles forming the C7 root in order to reduce morbidity in the healthy extremity. A total of 111 procedures were performed by this author and a long-term follow-up could be carried out in 21 patients. Motor results were worse than those of Gu, with 29% wrist and finger motor recovery and a similar rate of sensory recovery. Only 3 out of 21 patients had a temporary motor deficit in wrist extension in the healthy extremity.

Using functional MR imaging, Oberlin (3) found bilateral motor cortex activity in patients who had undergone C7 root nerve transfers. This explains the synkinesis in both arms when the healthy arm is moved. This complication could eventually bring to abandon the contralateral C7 root transfer, but this is still to be determined (Oberlin, personal communication).



### *Hypoglossal Nerve Transfer*

There is literature consensus regarding the poor results in brachial plexus function recovery obtained with the transfer of the hypoglossal nerve in contrast with the successful hypoglossal-facial nerve anastomosis.

Malessy et al (22) reported a series of 14 patients who underwent hypoglossal nerve transfer to neurotize the C5 root or the axillary, suprascapular or musculocutaneous nerves. A sural nerve graft was always used. Muscular contraction was graded up to BMRC 3 in some cases, but voluntary control of reinnervated muscles was absent in all cases.

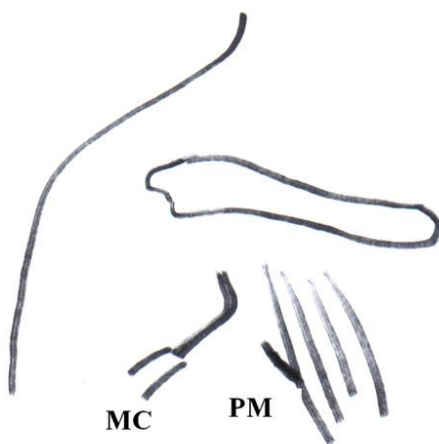
Ferraresi (9) reported similar results in 7 cases where, instead of all the nerve, a hemihypoglossal nerve transfers was used to reduce morbidity of swallowing and speech.

### *Triceps Nerve Transfers*

Recently, Bertelli (5) suggested the transfer of nerve branches innervating the triceps muscle, such as the branch for the long head, to neurotize the axillary nerve. In 10 cases the axillary and suprascapular nerves were neurotized with a triceps nerve branch and the spinal accessory nerve, respectively. Active abduction recovery and external rotation averaged 92° and 93°, respectively. These results appear promising and are waiting to be confirmed in larger series.

### *Medial Pectoral Nerve Transfer*

Transfer of the medial pectoral nerve was initially popularized by Brandt (6) (Fig. 7) and Samardzic (37, 38, 39).



This medial pectoral nerve can be connected directly to musculocutaneous nerve at the level of the distal axilla without using a nerve graft: Samardzic obtained successful reinnervation of the musculocutaneous nerve in 85.7% of 14 patients, and of the axillary nerve in 81.8% of 14 patients.

Despite this good outcome, transfer of the medial pectoral nerve is criticized because it causes loss of arm adduction that precludes useful holding of objects against the trunk (25).

### *Comparative Studies of Different Nerve Transfer Techniques*

In a prospective randomized trial, Waikakul (48) assessed the functional results after neurotization of the musculocutaneous nerve using transfer of either intercostal nerves (75 patients) or spinal accessory nerve (130 patients).

Clinical results were good or very good in 83% of the cases treated using the spinal accessory nerve, and in 64% of those treated using intercostal nerves. Furthermore, transfer of spinal accessory nerve was superior to that of intercostal nerves also for what concerns operative time, postoperative complications and need of blood transfusions.

However, sensory function in the area of the musculocutaneous nerve better improved in the cases treated with transfer of intercostal nerves.

Merrel (27) discussed the outcome of 1088 neurotizations within the framework of a meta-analysis of English literature. Regarding 965 cases of musculocutaneous nerve neurotization, 71% achieved MRC 3 biceps muscle strength. Fifty-four % of musculocutaneous nerves were neurotized using intercostal nerves and in 72% of these cases clinical results were good. Thirty-six % of musculocutaneous nerves were neurotized with spinal accessory and the clinical results were favorable in 77% of them. Another thing was that clinical results using intercostal nerves were better if nerve grafts were not used. Of all musculocutaneous neurotization procedures evaluated in this meta-analysis, ulnar nerve transfer to biceps branch showed the better results, with 94% M3 or higher; reported cases, however, are few compared with previous techniques.

In the same study (27), active shoulder abduction was evaluated in 123 cases and 73% of them achieved M3 or higher results. Neurotization of the suprascapular nerve-supraspinous muscle was successful in 92%, of cases whereas neurotization of the axillary nerve-deltoid muscle was successful in 69% of cases.

### **Conclusions**

- In cases of BPI with root avulsion, neurotization procedures are the only possibilities to restore some function in the injured arm. Currently around ten different donor nerves can be used.
- To restore active mobility of both shoulder and elbow, the suprascapular and musculo-cutaneous nerves are successfully reinnervated using the spinal accessory and phrenic nerve transfers, closely followed by intercostal nerve transfers.. Another possibility is given by contralateral C7 root transfer, although associated morbidity of the healthy arm and upper extremity synkinesis would pose a limit to its use. Hypoglossal nerve transfer have achieved poor results.
- There is almost unanimous literature consensus on the difficulty to obtain function recovery of the forearm, wrist and hand.

- In incomplete BPI with preservation of forearm and hand function and discrete compromise of shoulder and elbow motility, Oberlin technique and its variants provide excellent results. Medial pectoral nerve transfer has limited indications because, as reported by some authors, it causes weakening of arm adduction. The transfer of a triceps nerve branch to the axillary nerve has recently showed interesting but still preliminary results.
- Since reconstruction options for repairing a severely BPI are currently manifold, controlled studies to accurately and definitively establish the indications of each technique should be carried out in the future.

## References

1. Allieu Y, Cenac P. Neurotization via the spinal accessory nerve in complete paralysis due to multiple avulsion injuries of the brachial plexus. *Clin Orthop Rel Res* 1988; 237: 67-74.
2. Alnot JY. Traumatic brachial plexus lesions in the adult: indications and results. *Microsurgery* 1995; 16:22-9.
3. Beaulieu JY, Blustajn J, Teboul F, Baud P, De Schonen S, Thiebaud JB, Oberlin C. Cerebral plasticity in crossed C7 grafts of the brachial plexus: an fMRI study. *Microsurgery* 26(4):303-10, 2006.
4. Bertelli JA, Ghizoni MF: Improved technique for harvesting the accessory nerve for transfer in brachial plexus injuries. *Neurosurgery* 58(4 Suppl 2):ONS-366-70, 2006.
5. Bertelli JA, Ghizoni MF: Reconstruction of C5 and C6 brachial plexus avulsion injury by multiple nerve transfers: spinal accessory to suprascapular, ulnar fascicles to biceps branch, and triceps long or lateral head branch to axillary nerve. *J Hand Surg Am*:29(1):131-9, 2004.
6. Brandt KE, Mackinnon SE: A technique for maximizing biceps recovery in brachial plexus reconstruction. *J Hand Surg Am* 18:726-733, 1993
7. Brunelli G, Monini L. Neurotization of avulsed roots of braquial plexus by means of anterior nerves of cervical plexus. *Clin Plastic Surg* 1984; 11:149-52.
8. Chalidapong P, Sananpanich K, Kraissarin j, Bumroongkit C: Pulmonary and biceps function after intercostal and phrenic nerve transfer for brachial plexus injuries. *J Hand Surg [Br]*. 29(1):8-11, 2004.
9. Ferraresi S, Garozzo D, Ravenni R, Dainese R, De Grandis D, Buffatti P. Hemihypoglossal nerve transfer in brachial plexus repair: technique and results. *Neurosurgery* 2002; 50: 332-335.
10. Friedman A, Nunley J, Goldner R, Oakes J, Goldner L, Urbaniak J. Nerve transposition for the restoration of elbow flexion following brachial plexus avulsion injuries. *J Neurosurg* 1990; 72:59-64.
11. Friedman A. Neurotization of elements of the braquial plexus. *Neurosurg Clin N Am* 1991; 2: 165-74.
12. Gu Y, Chen DS, Zhang GM, Cheng XM, Zhang LY, Cai PQ et al. Long-term functional results of contralateral C7 transfer. *J Reconstr Microsurg* 1998; 14: 57-9.
13. Gu Y, Ma M. Use of frenic nerve for brachial plexus reconstruction. *Clin Orth and Rel Res* 1996; 323: 119-21.

14. Gu Y, Wu M, Zhen Y, Zhao J, Zhang G, Chen D et al. Phrenic nerve transfer for brachial plexus motor neurotization. *Microsurgery* 1989; 10:287-9.
15. Gu Y, Zhang G, Chen D, Yan J, Cheng X, Chen L. Seventh cervical root transfer from the contraletarl healthy side for treatment of brachial plexus root avulsions. *J Hand Surg* 1992; 17B: 518-21.
16. Guan SB, Hou CL, Chen DS, Gu YD: Restoration of shoulder abduction by transfer of the spinal accessory nerve to suprascapular nerve through dorsal approach: a clinical study. *Chin Med J* 119(9): 707-712, 2006.
17. Kawai H, Kawabata H, Masada K, Ono K, Yamamoto K, Tsuyuguchi T. Nerve repairs for traumatic brachial plexus palsy with root avulsion. *Clin Orthop* 1988; 237: 75-86.
18. Kline D. Perspectives concerning brachial plexus injury and repair. *Neurosurg Clin N Am* 1991; 2: 151-64.
19. Leechavengvongs S, Witoonchart K, Uerpairojkit Ch, Thuvasethakul PH, Ketmalasri W. Nerve transfer to biceps muscle using a part of the ulnar nerve in brachial plexus injury (upper arm type): a report of 32 cases. *J Hand Surg* 1998; 23A: 711-6.
20. Liverneaux PA, Diaz LC, Beaulieu JY, Durand S, Oberlin, C: Preliminary results of double nerve transfer to restore elbow flexion in upper type brachial plexus palsies. *Plast Reconstr Surg* 117(3):915-9, 2006.
21. Luedemann W, Hamm M, Blömer U, Samii M, Tatagiba M. Brachial plexus neurotization with donor frenic nerves and its effect on pulmonary function. *J Neurosurg* 2002; 96: 523-6.
22. Malessy M, Hoffman C, Thomeer R. Initial report on the limited value of hipoglossal nerve transfer to treat brachial plexus root avulsions. *J Neurosurg* 1999; 91:601-4.
23. Malessy MJ, Bakker D, Dekker AJ, et al: Functional magnetic resonance imaging and control over the biceps muscle after intercostal-musculocutaneous nerve transfer. *J Neurosurg* 98:261-268, 2003.
24. Malessy MJ, de Ruiten GC, de Boer KS, Thomeer RT: Evaluation of suprascapular nerve neurotization after nerve graft or transfer in the treatment of brachial plexus traction lesions. *J Neurosurg* 101(3):377-89, 2004.
25. Malessy MJ, Thomeer RT, van Dijk JG: Changing central nervous system control following intercostal nerve transfer. *J Neurosurg* 89:568-574, 1998
26. McGillicuddy JE. Clinical decisión making in brachial plexus injuries. *Neurosurg Clin N Am* 1991; 2: 137-50.
27. Merrell GA, Barrie K, Katz DL, Wolfe SW. Results of nerve transfer techniques for restoration of shoulder and elbow function in the context of a meta-analysis of the English literature. *J Hand Surg* 2001; 26A: 303-14.
28. Millesi H. Brachial plexus injuries. *Clin Plastic Surg* 1984; 11: 115-20.
29. Narakas AO, Hentz VR. Neurotization in brachial nerve plexus injuries. Indications and results. *Clin Orthop Rel Res* 1988; 237:43-56.
30. Narakas AO. Thoughts on neurotization or nerve transfers for irreparable nerve lesions. *Clin Plastic Surg* 1984; 11: 153-9.
31. Oberlin C, Bèal D, Leechavengvongs S, Salon A, Dauge MC, Sarcy JJ. Nerve transfer to the biceps muscle using a part of the ulnar nerve for C5-C6 avulsion of the brachial plexus: anatomical study and report of four cases. *J Hand Surg* 1994; 19A:232-7.
32. Oberlin C, Ameur NE, Teboul F, Beaulieu JY, Vacher C: Restoration of Elbow Flexion in Brachial Plexus Injury by Transfer of Ulnar Nerve Fascicles

- to the Nerve to the Biceps Muscle. *Tech Hand Up Extrem Surg* 6(2):86-90, 2002.
33. Oberlin C: Brachial plexus palsy in adults with radicular lesions, general concepts, diagnostic approach and results. *Chir Main* 22(6):273-84, 2003.
  34. Okinaga S, Nagano A. Can vascularization improve the surgical outcome of the intercostal nerve transfer for traumatic brachial plexus palsy? A clinical comparison of vascularized and non-vascularized methods. *Microsurgery* 1999; 19: 176-80.
  35. Richardson PM. Recovery of biceps function after delayed repair for brachial plexus injury. *J Trauma* 1997; 42: 791-2.
  36. Ruch D, Friedman A, Nunley J. The restoration of elbow flexion with intercostals nerve transfers. *Clin Orth Rel Res* 1995; 314: 95-103.
  37. Samardzic M, Grujicic D, Antunovic V. Nerve transfer in brachial plexus traction injuries. *J Neurosurg* 1992; 76:191-7.
  38. Samardzic M, Grujicic D, Rasulic L, et al: Transfer of the medial pectoral nerve: myth or reality? *Neurosurgery* 50: 1277-1282, 2002
  39. Samardzic M, Rasulic L, Grujicic D, et al: Results of nerve transfers to the musculocutaneous and axillary nerves. *Neurosurgery* 46:93-103, 2000
  40. Samii A, Carvalho G, Samii M. Brachial plexus injury: factors affecting functional outcome in spinal accessory nerve transfer for the restoration of elbow flexion. *J Neurosurg* 2003; 98: 307-12.
  41. Sedel L. Repair of traction lesions of the brachial plexus. *Clin Orthop Rel Res* 1988; 237: 62-6.
  42. Songchaoren P, Mahaisavariya B, Chotigavanich CH. Spinal accessory neurotization for restoration of elbow flexion in avulsion injuries of the brachial plexus. *J Hand Surg* 1996; 21A:387-90.
  43. Songchaoren P, Wongtragul S, Mahaisavariya B. Hemi-cotralateral C7 transfer to median nerve in the treatment of root avulsion brachial plexus injury. *J Hand Surg* 2001; 26A: 1058-64.
  44. Terzis J, Vekris M, Souracos P. Outcomes of brachial plexus reconstruction in 204 patients with devastating paralysis. *Plastic Rec Surg* 1999; 104: 1221-40.
  45. Terzis JK, Kostas I: Suprascapular nerve reconstruction in 118 cases of adult posttraumatic brachial plexus. *Plast Reconstr Surg*. 117(2):613-29, 2006.
  46. Tsuyama N, Hara T. Reconstructive surgery for traumatic braquial plexus injuries. *Clin Orthop Surg* 1968;3:675-87.
  47. Tung T, Novak C, Mackinnon SE. Nerve transfers to the biceps and brachialis branches to improve elbow flexion strength after brachial plexus injuries. *J Neurosurg* 2003; 98: 313-8.
  48. Waikanul S, Wongtragul S, Vanadurongwan V. Restoration of elbow flexion in brachial plexus avulsion injury: Comparing spinal accessory nerve with intercostals nerve transfer. *J Hand Surg* 1999; 24A: 571-7.
  49. Xu WD, Gu YD, Xu JG, Tan LJ: Full-length phrenic nerve transfer by means of video-assisted thoracic surgery in treating brachial plexus avulsion injury. *Plast Reconstr Surg* 110(1): 104-109, 2002.
  50. Yamada S, Lonser R, Iacono RP, morenski JD, Bailey L. Bypass coaptation procedures for cervical root avulsion. *Neurosurgery* 1996; 38: 1145-52.

## Figure Legends

Figure 1: Spinal accessory nerve transfer for musculocutaneous nerve reinnervation. SAN: spinal accessory nerve, IJG: interposition jump graft, MCN: musculocutaneous nerve.

Figure 2: Phrenic nerve transfer for musculocutaneous nerve reinnervation. PN: phrenic nerve, IJG: interposition jump graft, MCN: musculocutaneous nerve.

Figure 3: Nerve transfer with some ulnar fascicles for musculocutaneous nerve reinnervation (Oberlin technique). UN: ulnar nerve, MCN: musculocutaneous nerve.

Figure 4: Intercostal nerve transfer for musculocutaneous nerve neurotization. ICN: intercostal nerves, MCN: musculocutaneous nerve.

Figure 5: C3 and C4 root transfers for C5 and C6 root neurotizations

Figure 6: Contralateral C7 root nerve transfer for musculocutaneous nerve neurotization. UN: ulnar nerve, as pedicled graft, MCN: musculocutaneous nerve.

Figure 7: Medial pectoral nerve transfer for musculocutaneous nerve neurotization. MPN: medial pectoral nerve, MCN: musculocutaneous nerve.

## Tables

**Table 1:** British Medical Research Council (MRC) scale of motor strength

Grade	Motor Strength
0	No muscular contraction
1	Some contraction
2	Non-antigravity active movement
3	Antigravity active movement
4	Active movement against resistance
5	Normal strength