

# **A New Classification Of Unruptured Middle Cerebral Artery Bifurcation Aneurysms.**

Yoko Kato  
Dept. of Neurosurgery  
Fujita Health University

## **Abstract**

MCA aneurysms comprise 20% to 25% of intracranial aneurysms. Majority of middle cerebral artery aneurysms are treated with microsurgical clipping. Most of the classifications are based on size, location or pathology which are effective for description but are less useful in preoperative planning and also in deciding the technique or type of clip application. The aim of our study was to study the morphological features of unruptured MCA bifurcation aneurysms which were influencing the techniques of clipping of these aneurysms and to attempt to subclassify unruptured middle cerebral artery aneurysms based on their preoperative 3D CTA and intraoperative characteristics so as to help in the intraoperative choice of technique and clip application respectively. The preoperative 3D CT angiography and intraoperative images along with the record of technique and type of clips of 141 unruptured MCA aneurysms operated at our center were studied retrospectively.

Unruptured MCA bifurcation aneurysms could be subclassified based on the similarities in morphological features which had influenced the clipping's techniques as recorded from their preoperative 3D CTA and intraoperative view into 5 types. We describe distinctive features of each type, discussing various techniques of clipping based on these subgroups. This new classification allowed us to describe several clipping approaches within the groups.

This classification based on the preoperative 3D CTA and intraoperative morphological features of aneurysm and parent vessels helps in the intraoperative choice of technique and type of clip application to tackle these aneurysms.

## **Introduction**

The middle cerebral artery (MCA) is one of the most common sites of cerebral aneurysms; MCA aneurysms comprise 20% to 25% of intracranial aneurysms with nearly 80% occurring at its bifurcation (1). Estimates of the frequency of incidental intracranial aneurysms range between 5% and 10%, while angiographic studies show a rate from 0.65% to 1%. (2, 3, 4, 5) In spite of the variable anatomy of the middle cerebral artery, these aneurysms tend to arise at the primary middle cerebral artery bifurcation and point away along the axis of the middle cerebral trunk (6, 7). Direct microsurgical repair is not least due to the complex neck configuration the most common method used to treat middle cerebral artery aneurysms. Microsurgical clipping of these aneurysms is easier than in other locations because of their peripheral location (6, 7, 8, 9, 10, 11, 12). Even in institutions in which endovascular treatment with Guglielmi detachable coil packing is the preferred treatment, majority of middle cerebral artery aneurysms are treated with microsurgical clipping (13). Factors like giant

size (15%), wide necks with major arterial branches arising at the base, the frequent need to reconstruct and preserve the MCA bifurcation, makes direct surgical approaches the procedure of choice. Morphology and the consequent Surgical clipping techniques in unruptured middle cerebral artery aneurysm are diverse. Some are simple while others need reconstruction of the bifurcation using multiple clips or vascular reconstructive procedures sometimes challenging even the most experienced surgeons. Most of the classifications of aneurysms are based on size, shape, location or pathology (14, 15).

Although these classifications are very effective for description and relation to the clinical picture, they are less useful in preoperative planning and also in deciding the technique or type of clip application. The objective of clipping in unruptured aneurysms is to reconstruct the vessel wall to qualities closest to the normal one and make it less prone for rupture, Then it appears logical that a classification using the extent and the location of parent vessel wall deficit may be useful for surgical planning. The aim of our study was to study the morphological features of unruptured MCA bifurcation aneurysms which were influencing the techniques of clipping of these aneurysms and to attempt to subclassify unruptured middle cerebral artery aneurysms based on their preoperative 3D CTA and intraoperative characteristics so as to help in the intraoperative choice of technique and clip application respectively.

## **Material and Methods**

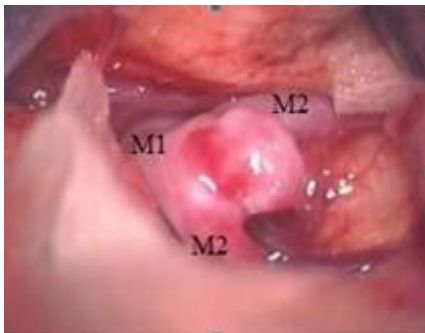Data regarding a total of 141 unruptured cerebral artery bifurcation aneurysms which were surgically clipped in the Department of Neurosurgery, Fujita Health University Hospital, Japan, from January 2004 to October 2006 were reviewed from the database. In all cases a three-dimensional CT angiography was done as preoperative investigation for diagnosis. The preoperative 3D CT angiography and intraoperative images along with the record of technique and type of clips were studied retrospectively. The morphological factors studied included size, shape, projection, relation of any branches at neck, extent of weakness in the vessel wall at origin of aneurysm, and atherosclerosis at neck, parent vessel and branches were noted.

All patients were operated electively by the two senior authors (H.S and Y.K) using standard pterional approach that Yasargil (11) popularized for middle cerebral artery aneurysms. The lateral sylvian fissure was opened sparing the sylvian veins and the middle cerebral branches were traced to the aneurysm and middle cerebral trunk (16). Standardized techniques with inhalatory and narcotic agents under mild hypothermia were used for anesthesia. Temporary clips were used only in some selected cases under intraoperative brain protection measures. In all cases after the final clip application the aneurysm and the MCA vessels were thoroughly inspected often with endoscopic review of blind areas. Intraoperative Doppler was used to confirm the patency of the M1 and M2 branches before and after clipping and clips were readjusted if necessary. Intraoperative angiography for middle cerebral artery aneurysms was not performed routinely but was used only when dealing with complex aneurysms, before and after the aneurysm has been clipped and the patency of the MCA, bifurcation and its branches confirmed.

There were 149 patients operated for unruptured MCA aneurysm for the period and complete records of 141 patients could be retrieved. They were 53 male and 88 Female. Their mean age was 59.4 yrs (ranging from 33 yrs to 76 yrs). They were 79 (56%) right side and 62 (44%) on left side. The commonest projection was anterolateral. Multiple aneurysms were present in 26 (18.4%).

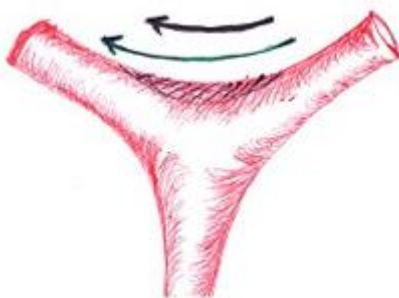Unruptured MCA bifurcation aneurysms could be subclassified based on the similarities in morphological features which were influencing the clipping techniques as recorded from their Preoperative 3D CTA and intraoperative view into 5 types. These types and the distinctive feature of each type are shown in Table 1. Atherosclerotic involvement of the vessel wall and aneurysm was noted.

Type I or simple aneurysms (fig 1a) were those which were seen as arising as a bulging from a well circumscribed weakness of the wall limited to the site of maximum haemodynamic stress at the bifurcation and not extending on to M1 in proximal direction.



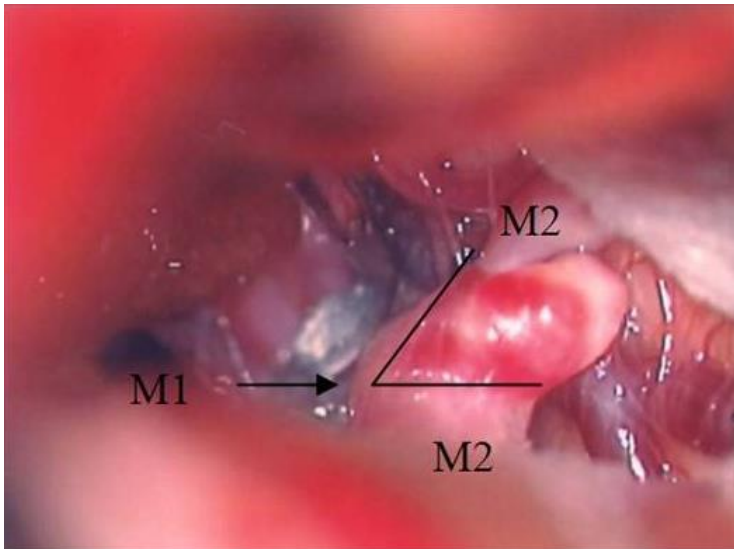
**Fig 1a** Intraoperative image showing a Type I or Simple Aneurysm

They usually had a well defined neck and often the long axis of orientation of the neck in these aneurysms was parallel to the plane where the M2 axis are laying at bifurcation (fig 1b).

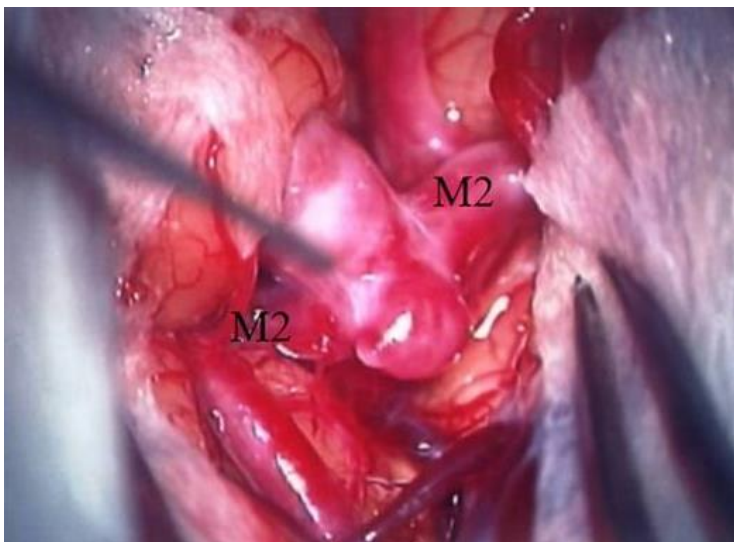


**Fig 1b** Drawing of the MCA bifurcation with axis of the M2 branches at bifurcation (green arrow) parallel to the axis of neck of aneurysm(black arrow)in type I aneurysm with shaded area indicating origin of the aneurysm.

Type II aneurysm, also called the central type (fig 2 a, b) had aneurysmal weak wall extending to portions of M1 proximally and often saddling over the bifurcation.

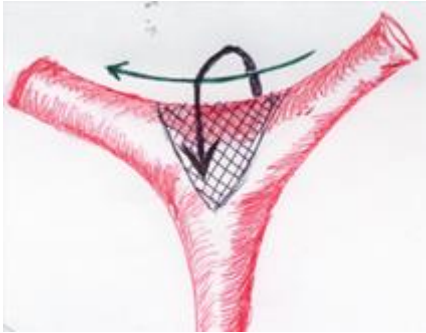

**Fig 2a** Intraoperative image showing a Type II or Central Aneurysm, The arrow points to M1 and the triangular aneurysmal weak wall extending to portions of M1 proximally shown



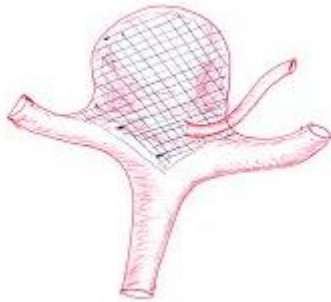
**Fig 2b** Multilobulated Type II aneurysm with neck seen saddling over the bifurcation.

Often the long axis of orientation of the neck in these aneurysms was perpendicular to the axis of M2 branches at bifurcation (fig 2c).

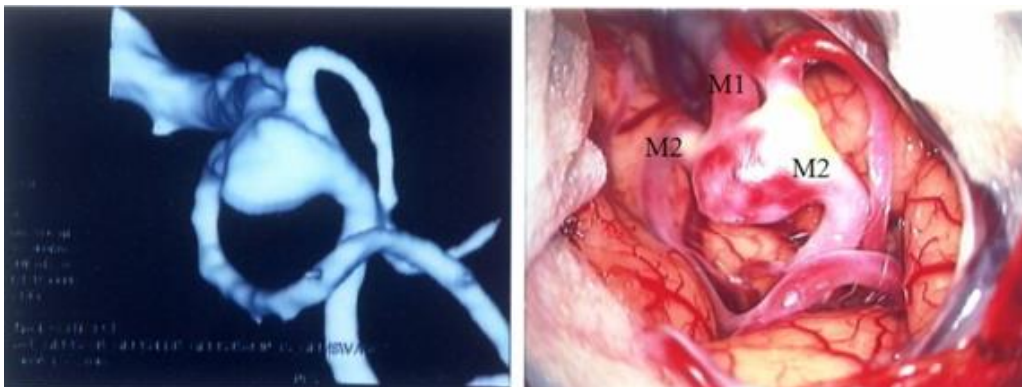


**Fig 2c** Drawing of the MCA bifurcation with axis of the M2 branches at bifurcation (green arrow) perpendicular to the axis of neck of aneurysm (black arrow) in type II aneurysm with shaded area indicating origin of the aneurysm extending to M1 proximally.

The neck in these aneurysms is complicated because of its orientation in multiple planes. Type III (fig 3 a, b) were those complicated neck aneurysms with a perforator or branch emerging at the neck of aneurysm.

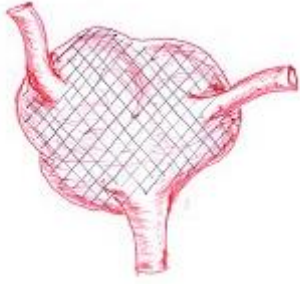


**Fig 3a** Drawing of the MCA bifurcation with a branch arising from the neck as in a type III aneurysm.

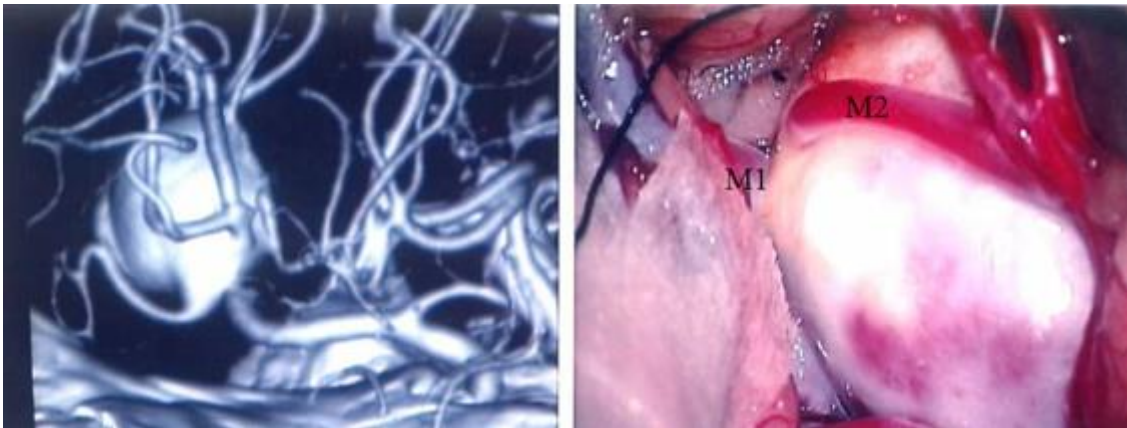


**Fig 3b** 3D CTA and intraoperative image of a type III aneurysm

Type IV or complex aneurysms (fig 4 a, b) were those aneurysms in which the M2 branches were seen to be arising from the aneurysm rather than M1 because of the circumferential involvement of the wall of M1 and /or M2. These were often giant MCA bifurcation aneurysms which incorporated the proximal portions of the branches and required reconstruction of the bifurcation.

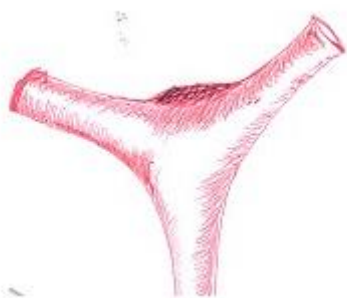


**Fig 4a** Drawing of a type IV aneurysm with M2 branches seen to be arising from the aneurysm rather than M1.



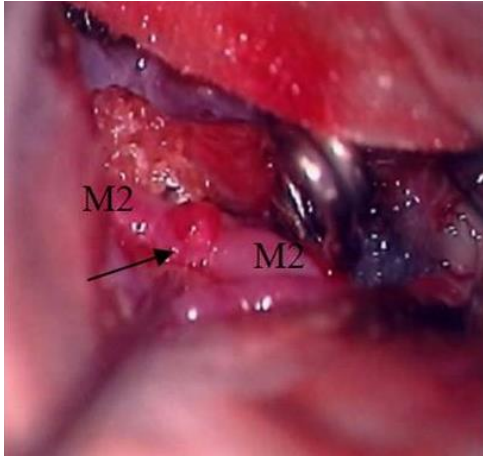**Fig 4b** 3D CTA and intraoperative image of a type IV aneurysm

Type V were blister aneurysms (fig 5 a, b) which were exposed while operating on an aneurysm at a different location. The various techniques of clipping are discussed based on these subgroups.



**Fig 5a** Drawing of a type V or Blister Aneurysm



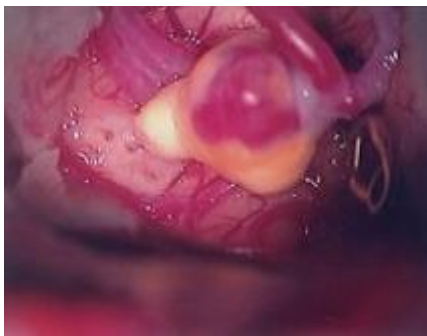

**Fig 5b** Intraoperative image of a type V aneurysm.

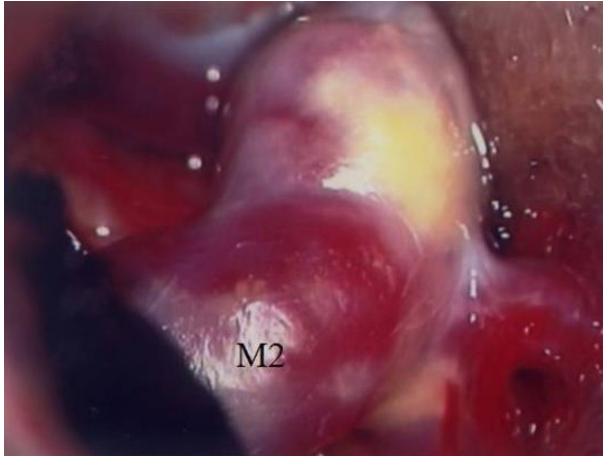## Results

The 141 patients who underwent clipping for unruptured MCA aneurysm were subdivided into the 5 types based on the similarities in morphological features which was influencing the techniques of clipping as recorded from their Preoperative 3D CTA and intraoperative view. There were 41(29.1%) Type I or simple aneurysms, 82 (58.2%) Type II or central aneurysms, 7(5%) Type III, 8 (5.7%) Type IV or complex aneurysms and 3 (2.1%) Type V or blister aneurysms. Type II aneurysms were the commonest type.

13 of these aneurysms had visible atherosclerotic changes at the neck or the parent vessel influencing the clipping technique (Fig 6, 7). Their distribution according to location of the atherosclerosis and type of aneurysm is shown in Table 2.



**Fig 6** Atherosclerosis involving the aneurismal wall



**Fig 7** Atherosclerosis at neck of aneurysm

In the entire group of MCA aneurysms studied a single clip could be used to obliterate 89 (65.4%) aneurysms, 2 clips were required in 37 (27.2%), 3 clips in 7 (5.1%), 4 clips in 1 (0.7%) aneurysm and 3 (2.1%) blister aneurysms were wrapped. The number of clips according to the type of aneurysm is shown in Table 3.

All Type I aneurysms could be obliterated using a single clip. 51/82 (62.2%) type II aneurysms could be clipped with a single clip while 31 required multiple clips of which only one required 3 clips. In Type III aneurysm 6/7 (86%) required 2 clips with one of them being a fenestrated type clip while 1 could be clipped with a single clip. In type IV all of them required multiple clips with 7 out of 8 requiring 3 or more clips. All blister aneurysms were wrapped. When the number of patients in each type along with the percentage of single and multiple clip application was studied (Table 4), It showed a progression from 100% single clip application in type I to 100% multiple clip application in type IV.

There was no mortality and there was only one complication in the form of transient weakness detected immediate post operatively which improved after the clips were repositioned at an immediate exploration in a type II aneurysm with atherosclerosis at neck. There was no residual deficit or morbidity.

## **Discussion**

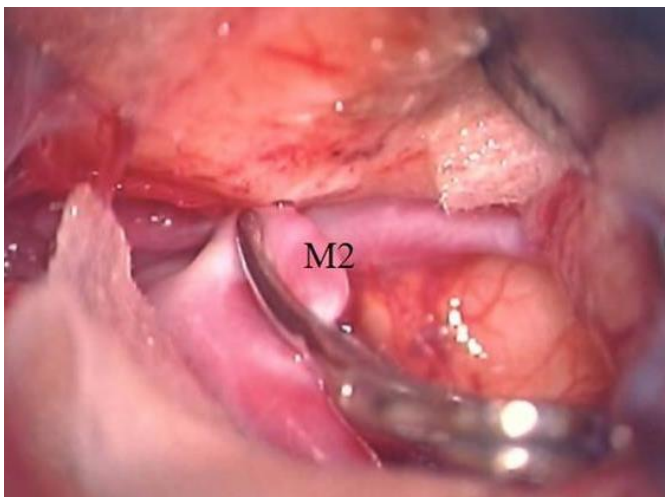
MCA bifurcation aneurysms constitute a majority of the unruptured aneurysms and are managed most often surgically. The general principles of approach and surgical techniques are well described in literature (7, 10, 11, 12, 17, 18). Most of the classifications of aneurysms are based on size or etiology (14, 15). Although these classification's were very effective for description they were less useful in preoperative planning, especially the intended technique or type of clip application, Therefore we attempted to sub classify them based on their morphological features which were influencing the techniques of clipping based on their preoperative 3D CTA and intraoperative characteristics, and by that to assist the intraoperative choice of technique and type of clip application to tackle these aneurysms. Preoperative evaluation with 3D-CT angiography and 3-DCT endoscopy enables information about the morphological features of unruptured aneurysms to be obtained with a low degree of invasiveness (19). The most important factors effecting the technique of clipping were the extent of parent



vessel wall weakness, the shape and orientation of the resulting neck, the presence of a branch at the neck and finally the existence of atherosclerosis of the parent vessel or aneurismal wall.

The multilobularity and complex shape of the dome rarely can affect the clipping. Thus our patients were classified into 5 Types based on the similarities in morphological features (the area of the weak wall ) which was influencing the techniques of clipping as recorded from their Preoperative 3D CTA and intraoperative view. Each group subdivided by presence or absence of atherosclerosis at the neck or the parent vessel, since it influenced the technique of clipping within the groups.

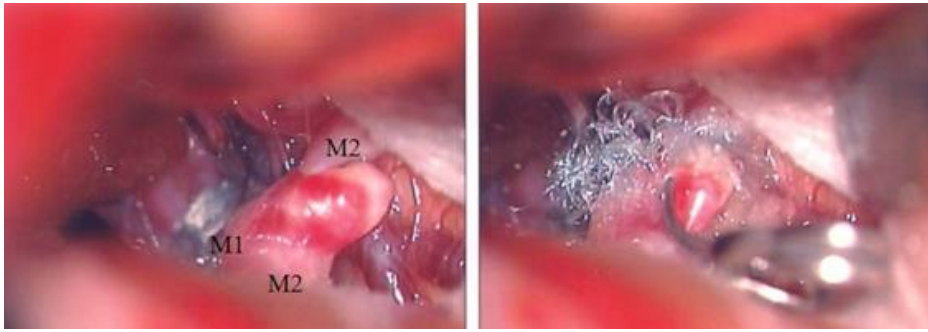
Type 1 aneurysms were simple aneurysms which had a well defined neck which could be obliterated with relative ease using a single clip. Often in these aneurysms the long axis of orientation of the aneurysm neck was parallel to the axis of M2 branches at bifurcation. Hence these aneurysms could be obliterated with clip such with the blades of the clip parallel to the long axis and could be obliterated with single clip with ease (fig 8).



**Fig 8** Clip application parallel to the axis of M2 branches at the bifurcation in a Type I aneurysm shown in fig 1a

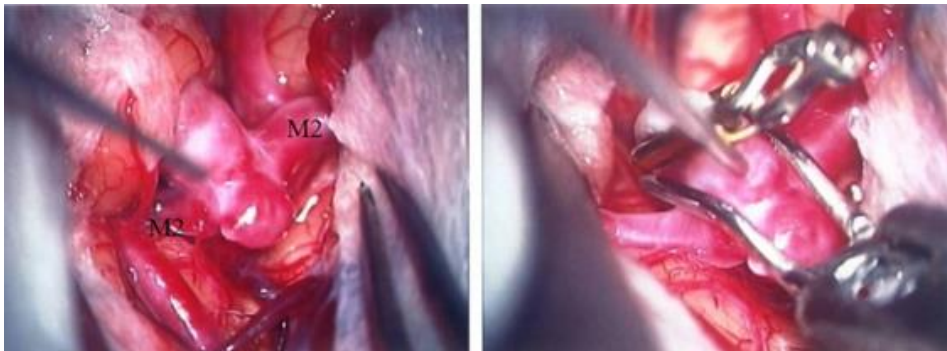
Type II or central aneurysms were the most common type. The distinctive feature of these aneurysms was the extension of the weak wall at the base of the aneurysm towards M1 over the bifurcation, most often saddling the bifurcation on both sides.

These aneurysms were arising at the bifurcation projecting away along the line of the main axis of M1 and splaying the branches at bifurcation. Most often the long axis of the neck of these aneurysms is perpendicular to the proximal branches at bifurcation hence a triangular portion of abnormal vessel wall can be seen extending into the bifurcation towards the M1. In this group the clip was placed along the axis of M1 perpendicular to the axis of M2 branches at the bifurcation since conventional clipping parallel to axis of M2 would leave a residual neck which is the triangular portion extending into the bifurcation (Fig 9).



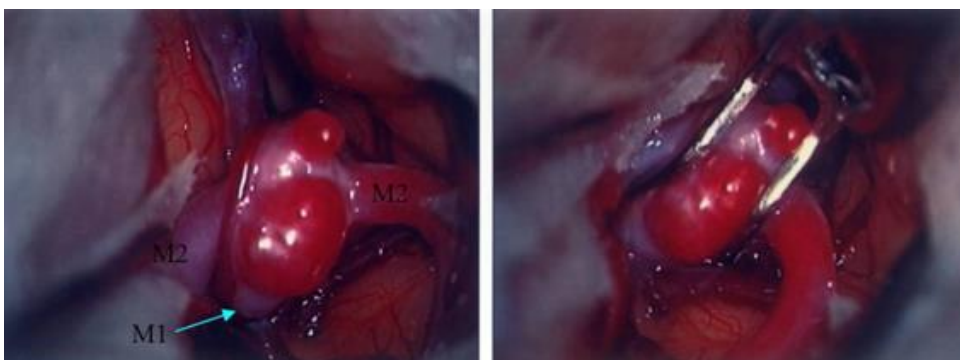
**Fig 9** Clip application parallel to the axis of M2 branches at the bifurcation in a Type II aneurysm shown in fig 2a with triangular portion of weak wall extending to M1 covered with Neobel

Shank clipping which is a method that uses a genu portion of bayonet clip is one method used in this type to avoid multiple clipping. In this type the best method is by using a crankshaft clip placed perpendicular to the bifurcation (Fig 10a).



**Fig 10a** Intraoperative image of a Type II aneurysm showing single clip application by Shank clipping method for aneurysm obliteration.

The residual neck formed by the original bayonet clip is completely occluded by a crankshaft clip (Osawa's modification) (20) or application of 2 clips was required if the extension on to M1 was too long (fig 10b).



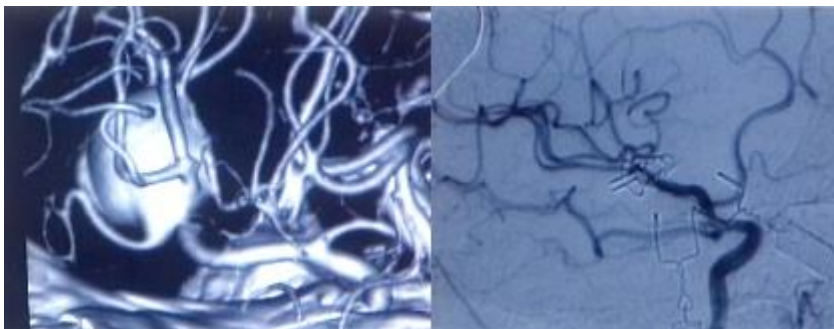
**Fig 10b** Intraoperative image of a Type II aneurysm showing multiple clip application for aneurysm obliteration.

The shape of the dome of these aneurysms did not affect the technique of clipping because some times remodelling of the aneurysm could be done with low bipolar cauterization to prepare them for clipping. This is accomplished by applying short bursts of bipolar current in low setting with an irrigation simultaneously to the aneurysm. This shrinks the aneurysm tissue and remodels the shape of it to allow a complete clipping. Sclerotic, calcified, or partially thrombosed lesions do not respond to this technique.

In type III aneurysms the neck were complicated by perforators at the neck which needed special attention during clipping. To avoid clipping a perforator or a branch at the neck of aneurysm, we used a fenestrated clip first, sparing the perforator and then we put a second clip for the remaining neck.

Other techniques used to preserve the perforating arteries behind the neck are, a closing and releasing maneuver, insertion of oxidized cellulose ball between the neck and perforators or protection of the perforators with silicone sheets (21). Endoscopic assistance is very useful in these types to look into the blind areas at the neck and preserve the perforators (22).

Type IV aneurysms could be described as those complex aneurysms in which there was further extension of the weak wall of the aneurysm incorporating the proximal portions of M2 branches and distal M1 into the aneurysm hence the M2 branches were seen to be arising from the aneurysm. In our study we had only 8 aneurysms which were complex and required multiple clips to reconstruct the bifurcation. 6 of them required 3 clips each, while 2 clips and 4 clips were used in the remaining 2 complex aneurysms. (fig 11).



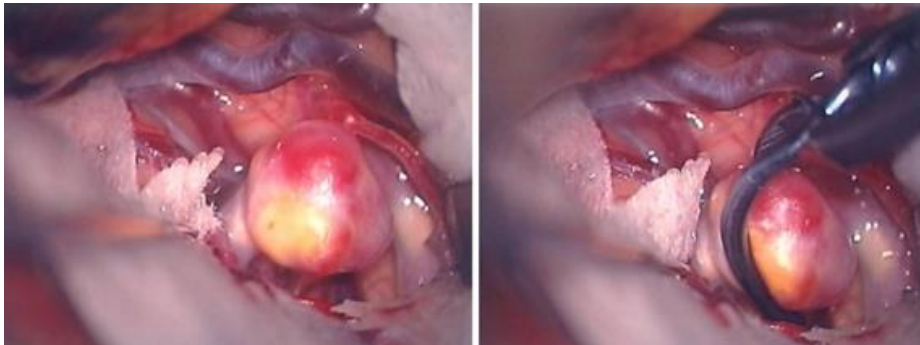
**Fig 11** Intra operative angiogram of Type IV aneurysm whose 3D CTA was shown in Fig 4b. It shows reconstruction of the bifurcation with 2 clips in place.

Sometimes these type of aneurysms may need special techniques like bypass or other vascular reimplantation procedures as described by Shekar et al (23). The surgical reconstruction of the bifurcation may be either using multiple clips in tandem fashion or major vascular reconstruction like direct suture repair, reimplantation or anastomosis of branches, bypass procedures or interposition grafts.

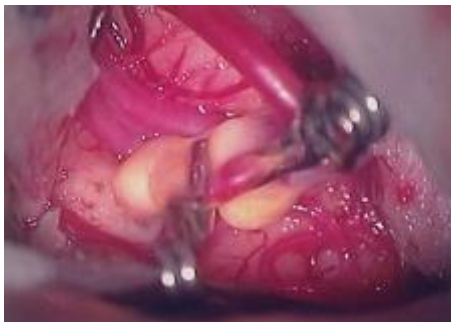Atherosclerotic changes at the neck and parent vessel modified the technique of clip application within all these groups.

The presence of atherosclerosis caused irregularity in thickness of the wall of the aneurysm and also caused disparity in the appearance of external caliber to the internal lumen of parent vessel at the neck (Fig 6, 7).

In these aneurysms it was difficult to maintain patency of the parent with conventional clipping due to significant atherosclerosis at neck of aneurysm. Hence obliteration of the weak wall of the aneurysm maintaining the patency of the vessels was done using a single clip slightly away from the neck (fig 12a) or multiple clips (fig 12b).



**Fig 12a** Intraoperative image of a type I aneurysm with clip placed away from neck due to atherosclerosis at neck.



**Fig 12b** Intraoperative image of a type I aneurysm with multiple clips placed away from neck to obliterate the weak wall of aneurysm.

Sometimes, if there was significant atherosclerosis of the parent vessel, multiple clips were used to reconstruct bifurcation anatomy maintaining patency of the vessel at the aneurysm neck after clipping. Sometimes the tips of the clips couldn't closed completely in large and giant aneurysms with thick walls. In these situations, we used Drake's tandem-clipping technique (17).

A fenestrated clip is used proximally so that the crotch of the fenestrated clip jaws is not held open by the aneurysm wall and allows the tips of the clip to close.

Then, we used a nonfenestrated clip to exclude the proximal portion of the aneurysm missed by the fenestration of the proximal clip. A thick wall of an aneurysm may, at times forces the clip on to the luminal origin of the branches. In these instances second permanent clip can be placed in tandem to the first clip immediately distal to the first clip away from the neck and the first clip

removed. Some authors have described thromboendarterectomy before clipping in such types of aneurysms (18).

In our series we had 1 type I, 10 type II and 2 typeIV aneurysms which had atherosclerosis of the parent vessel or neck requiring the clip to be placed a little distal on the neck to maintain patency of the parent vessel. Partial clipping of the weak portion of the wall was done in some with significant stenosis at the neck extending on to the parent vessel.

We didn't find aneurysms in trifurcation MCA in our series. However, the same subclassification may be applied to them. If one branch is close to the neck, then is treated as a complicated neck or Type III aneurysm.

## Conclusions

We have made a classification of unruptured MCA aneurysms which constitute the most common type of unruptured aneurysm. This classification was based on their preoperative 3D CTA and intraoperative characteristics of the vascular wall with the intention to help the pre and intraoperative clipping plan. The groups outlined make it possible the establishment of common technical approach to clipping, so as to help in the intraoperative choice of technique and type of clip application to tackle these aneurysms. However further studies are required to classify aneurysms which will practically help in management of aneurysms.

## Tables

**Table 1:** British Medical Research Council (MRC) scale of motor strength

Type of aneurysm	Distinctive feature
I Simple	Weak aneurismal wall well circumscribed to site of maximum haemodynamic stress, no extension to M1 proximally
II Central type	Weak Aneurismal wall extending on M1 trunk
III Complicated neck	Branch at the neck of aneurysm
IV Complex	M2 branch arising from the aneurysm sac
V	Blister aneurysms

*The presence of atherosclerosis was marked within type as AN if present at neck and AP if involving the parent vessel or ANP if both involved.*

**Table 2:** Distribution of atherosclerosis within the aneurysm types

<i>Type of aneurysm</i>	<i>Atherosclerosis</i>		
	<i>Neck</i>	<i>Parent vessel</i>	<i>Both</i>
I		1	
II	6	3	1
III			
IV	1		1
V			

**Table 3:** Distribution of the number of clips used with each type of aneurysm

<i>Type of aneurysm</i>	<i>Number of clips used</i>				
	<b>0</b>	<b>1</b>	<b>2</b>	<b>3</b>	<b>4</b>
I		41			
II		51	30	1	
III		1	6		
IV	-	-	1	6	1
V	3	-			

**Table 4:** Distribution of single or multiple clipping with each aneurysm type

<i>Type of aneurysm</i>	<i>Number of patients</i>	<i>Percentage of clip usage</i>
I	41 (29.1%)	100% Single
II	82 (58.2%)	62.2% Single, 37.8% Multiple
III	7 (5%)	85.7% Multiple
IV	8 (5.7%)	100% Multiple
V	3 (2.1%)	Wrap
Total	141	



## References

1. Kassell NF, Torner JC, Haley EC, Jane JA, Adams HP, Kongable GI. The international cooperative study on the timing of aneurysm surgery, I overall management results and , II: Surgical results. *J Neurosurg* 73: 18-47,1990.
2. Atkinson JLD, Sundt TM Jr, Houser OW, et al. Angiographic frequency of anterior circulation intracranial aneurysms. *J Neurosurg* 1989; 70: 551-555.
3. Chason JL, Hindman WM. Berry aneurysms of the circle of Willis: results of a planned autopsy study. *Neurology* 1958; 8: 41-42.
4. McCormick WF. Problems and pathogenesis of intracranial arterial aneurysms. In: Moossy J, Janeway R, eds. 7th Conference: Cerebrovascular Diseases. New York: Grune & Stratton, 1971: 217-231.
5. Winn HR, Taylor J, Kaiser DL. Prevalence of asymptomatic incidental aneurysms: review of 4,568 arteriograms. *Stroke* 1983; 14: 121.
6. Rinne J, Hernesniemi J, Niskanen M, Vapalahti M: Analysis of 561 patients with 690 middle cerebral artery aneurysms: Anatomic and clinical features as correlated to management outcome. *Neurosurgery* 38: 2-11, 1996.
7. Sundt TM Jr: Part II: Aneurysms of the anterior circulation—Middle cerebral artery, in Sundt TM Jr (ed): *Surgical Techniques for Sacular and Giant Intracranial Aneurysms*. Baltimore, Williams & Wilkins, 1990, pp 179-212.
8. Ebina K, Shimizu T, Sohma M, Iwabuchi T: Clinico-statistical study on morphological risk factors of middle cerebral artery aneurysms. *Acta Neurochir (Wien)* 106: 153-159, 1990.
9. Kodama N, Ebina T, Fujiwara S, Mineura K, Suzuki J: Surgical treatment of the middle cerebral artery aneurysm: From the experiences of 174 cases [in Japanese]. *No Shinkei Geka* 7: 71-78, 1979.
10. Yasargil MG: Middle cerebral artery aneurysms, in *Microneurosurgery: Clinical Considerations, Surgery of the Intracranial Aneurysms and Results*. Stuttgart, Georg Thieme, 1984, vol II, pp 124-164.
11. Yasargil MG: General operative techniques, in *Microneurosurgery: Microsurgical Anatomy of the Basal Cisterns and Vessels of the Brain*. Stuttgart, Georg Thieme, 1984, vol I, pp 208-271.
12. Pasztor E, Vajda J, Juhasz J, Toth S, Orosz E, Horvath M: The surgery of middle cerebral artery aneurysms. *Acta Neurochir (Wien)* 82: 92-101, 1986.
13. Regli L, Uske A, de Tribolet N: Endovascular coil placement compared with surgical clipping for the treatment of unruptured middle cerebral artery aneurysms: A consecutive series. *J Neurosurg* 90: 1025-1030, 1999.
14. Turnbull H.M: Intracranial aneurysms. *Brain* 41:50-56,1918.
15. Wiebers D.O, Whisnant J.P, O'Fallon W.M: The natural history of unruptured intracranial aneurysm. *N Engl J Med* 304: 696-698,1981.
16. Pritz MB, Chandler WF: The transsylvian approach to middle cerebral artery bifurcation/trifurcation aneurysms. *Surg Neurol* 41: 217-220, 1994
17. Sundt TM Jr: Part I: Basic considerations—Basic principles and techniques, in Sundt TM Jr (ed): *Surgical Techniques for Sacular and Giant Intracranial Aneurysms*. Baltimore, Williams & Wilkins, 39-58,1990.
18. Chyatte, Douglas, Porterfield, Rebecca R.N. Nuances of middle cerebral aneurysm microsurgery. *Neurosurgery* 48(2): 339-346,2001.
19. Kato Y, Sano H, Katada K, Ogura Y, Hayakawa M, Kanaoka N, Kanno T. Application of three-dimensional CT angiography (3D-CTA) to cerebral aneurysms. *Surg Neurol*. 1999 Aug;52(2):113-21; discussion 121-2.
20. Osawa M, Obinata C, Kobayashi S, Tanaka Y. Newly designed bayonet clips for complicated aneurysms: technical note. *Neurosurgery* 36:425-427,1995.

21. Kodama N, Matsumoto M, Sasaki T. Techniques to preserve arteries around the aneurysm. *Surgery for Cerebral Stroke*:585-589,1991.
22. Kato Y, Sano H, Nagahisa, Iwata.S, Yoshida K, Yamamoto K, Kanno T. Endoscope-assisted Microsurgery for cerebral aneurysms. *Minim Invas Neurosurg* 43:91-97,2000.
23. Laligam N.Shekar, D.Stimac, A. Bakir, R. Rak. Reconstruction options for complex middle cerebral artery aneurysms. *Operative Neurosurgery* 56 (1):66-74, Jan 2005